

## **Pancreas Histology of Hyperglycemia of Mice (*Mus musculus L.*) After Treatment Basil (*Ocimum x africanum Lour.*) Leaf Extract and Papaya (*Carica papaya L.*)**

### **Histologi Pankreas Mencit (*Mus musculus L.*) Hiperglikemia Setelah Perlakuan Ekstrak Daun Kemangi (*Ocimum x africanum Lour.*) dan Pepaya (*Carica papaya L.*)**

**Elsa Safitri<sup>1</sup>, Sutyarso<sup>1</sup>, Sri Wahyuningsih<sup>\*1</sup>, Rochmah Agustrina<sup>1</sup>**

<sup>1</sup>Department of Biology, Faculty of Mathematics and Natural Sciences,  
University of Lampung, Lampung 35141 Indonesia

\*Correspondent Author: [wahyu6125@yahoo.co.id](mailto:wahyu6125@yahoo.co.id)

#### **ABSTRACT**

Hyperglycemia is a condition in which the level of glucose in the blood is abnormally high. Hyperglycemia is caused by disturbances in the metabolic system in secreting insulin. Hyperglycemia if left unchecked can cause a disease which is usually called diabetes. Basil (*Ocimum x africanum Lour.*) and papaya (*Carica papaya L.*) leaf extracts can reduce blood glucose levels in people with diabetes mellitus because they contain active compounds of flavonoids, alkaloids and tannins which function as anti-diabetics. The aim of this study was to examine the effectiveness of the effects of basil and papaya leaf in affecting the level of islet damage, and repairing pancreatic histological damage in hyperglycemic mice. This study used a completely randomized design with 5 treatment groups and 5 replications. Group K(N) as normal control, group K(+) as positive control, group K (-) as negative control, group P 1 (alloxan induced and treated with ethanol extract of basil leaves 24.5 mg/35g BW mice) 14 days oral), P 2 group (induced by alloxan and treated with papaya leaf ethanol extract 24.5 mg/35 g BW mice (14 days oral). Data on the level of histological damage to the pancreas of hyperglycemic mice were analyzed using the Kruskal-Wallis method and the Wilcoxon-MannWhitney test at a significant level of 5%. Data histological appearance of the Langerhans were analyzed descriptively. The results showed basil leaf extract and papaya had an effect on the level of damage to the pancreas of mice, basil leaf extract was effective compared to papaya in histological repair of the mice pancreas.

**Keywords:** Alloxan, *Carica papaya L.*, Hyperglycemia, *Ocimum x africanum Lour.*

#### **ABSTRAK**

Hiperglikemia adalah suatu kondisi di mana kadar glukosa dalam darah sangat tinggi. Hiperglikemia disebabkan oleh gangguan pada sistem metabolisme dalam mensekresi insulin. Hiperglikemia jika dibiarkan dapat menimbulkan penyakit yang biasa disebut diabetes. Ekstrak daun kemangi (*Ocimum x africanum Lour.*) dan pepaya (*Carica papaya L.*) dapat menurunkan kadar glukosa darah pada penderita diabetes melitus karena mengandung senyawa aktif flavonoid, alkaloid dan tanin yang berfungsi sebagai anti diabetes. Tujuan penelitian ini adalah untuk mengetahui efektivitas efek daun kemangi dan daun pepaya dalam mempengaruhi tingkat kerusakan pulau, dan memperbaiki kerusakan histologis pankreas pada mencit hiperglikemik. Penelitian ini menggunakan rancangan acak lengkap dengan 5 kelompok perlakuan dan 5 ulangan. Kelompok K(N) sebagai kontrol normal, kelompok K(+) sebagai kontrol positif, kelompok K(-) sebagai kontrol negatif, kelompok P 1 (diinduksi aloksan dan diberi perlakuan ekstrak etanol daun kemangi 24,5 mg/35g BB mencit) 14 hari oral), kelompok P 2 (diinduksi aloksan dan diberi perlakuan ekstrak etanol daun pepaya 24,5 mg/35 g BB mencit (14 hari oral). Data tingkat kerusakan histologis pankreas mencit hiperglikemik dianalisis menggunakan Kruskal-Wallis metode dan uji Wilcoxon-MannWhitney pada taraf signifikan 5%. Data gambaran histologis Langerhans dianalisis secara deskriptif. Hasil penelitian menunjukkan ekstrak daun kemangi dan pepaya berpengaruh terhadap tingkat kerusakan pankreas mencit, ekstrak daun kemangi efektif dibandingkan pepaya dalam perbaikan histologis pankreas mencit.

**Kata Kunci:** Aloksan, *Carica papaya L.*, Hiperglikemia, *Ocimum x africanum Lour*

## INTRODUCTION

Hyperglycemia occurs as a result of excessive reactive oxygen species (ROS) that encourage oxidative stress on pancreatic  $\beta$ -cells and inhibited insulin production. Hyperglycemia if it occurs continuously can cause diabetes mellitus (Rahman and Wati, 2016). The pancreas is one of the organs that can be damaged by diabetes. The state of hyperglycemia tends to have an unfavorable effect on the health of the body, because high blood glucose levels tend to encourage the formation of free radicals or reactive oxygen species through oxidation-reduction mechanisms by encouraging more electron donors into the electron transport chain in the mitochondria (Brownlee, 2001). Basil plants (*Ocimum x africanum* Lour.) can be used as a medicine for people with diabetes mellitus, namely in the leaves. Basil plants can generally be found easily and are usually used as fresh vegetables in food. Basil has crude fiber which is known to reduce cholesterol levels and blood sugar levels and reduce the risk of hypertension and cardiovascular disease (Ikhlas, 2013). Basil has active compounds, namely tannins, flavonoids, saponins, and alkaloids (Wibowo, 2012). Besides basil, papaya leaves can also be used as anti-hyperglycemic because papaya leaf extract contains alkaloids, flavonoids, glycosides, saponins, tannins and steroids/triterpenoids. Most plants that have been found to contain glycosides, alkaloids, terpenoids, flavonoids have an effect as antidiabetics. Based on the description above, researchers are interested in conducting further research, to determine the effectiveness of basil leaf extract (*Ocimum x africanum* Lour.) and papaya leaf extract (*Carica papaya* L.) in repairing damage to pancreatic histology tissue of hyperglycemia mice. This study is expected to be a new source of information for the community about the effectiveness of basil leaf extract and papaya leaves in treating diabetes mellitus.

## MATERIALS AND METHOD

### Location and time

The first stage was maceration of basil leaves and papaya leaves conducted in the Botany Laboratory, Department of Biology FMIPA, University of Lampung. The second stage is the maintenance of test animals, alloxan induction, administration of test materials in the form of basil (*Ocimum x africanum* Lour.) and papaya (*Carica papaya* L.) leaf extracts orally and necropsy of test animals carried out in the Zoology Laboratory, Department of Biology FMIPA, University of Lampung. The third stage is the process of making pancreatic histology preparations and observations carried out at the Histology and Pathology Laboratory, Faculty of Medicine, University of Lampung.

### Method

This study used a completely randomized design method with 5 groups and 5 replications. Group K(N) as a normal control, group K(+) as a positive control (induced alloxan and given glibenclamide), group K(-) as a negative control (induced alloxan), Group P1 (induced alloxan and treated with basil leaf ethanol extract 24.5 mg / 35g BB mice (14 days orally), group P2 (induced alloxan and treated with papaya leaf ethanol extract 24.5mg/ 35g BB mice (14 days orally).

### Preparation of materials

Preparation of materials in this study is the manufacture of ethanol extract of basil leaves for administration in P1, ethanol extract of papaya leaves for administration in P2, and glibenclamide suspension for administration in K(+). Basil leaves were obtained from plantations in the Metro City area and papaya leaves were obtained from papaya plantations in Central Lampung district Bangun Rejo District, basil and papaya leaves were selected the best (basil leaves all parts of the leaves except the top of the leaves and for papaya leaves starting from the third to fifth leaf blade) and washed with running water. Next, basil leaves and papaya leaves were dried for 24 hours, then oven at 40°C for 24 hours. The dried leaves were pulverized using a blender until they were powdered, the powder of each leaf was macerated using 96% ethanol for 3x24 hours. After that, filtering the macerate using a buchne funnel until a filtrate is obtained, the filtrate is concentrated using a rotary evaporator at 50oC to obtain a thick extract, then put in the oven until it becomes a paste. Making glibenclamide suspension is by calculating the use of drugs that are usually used by humans and then converted to mice. Conversion of human doses to mice using the Laurence and Bacharach conversion table (1964) the human to mice conversion rate is 0.0026. The manufacturing process is by grinding the glibenclamide tablet drug and then weighing the average dose of mice body weight. Each test material was dissolved by 1% Na-CMC.

### Test animals

The test animals used in this study were 25 male mice aged 3-4 months with an average body weight of 35 grams. Mice were obtained from mice breeders in Lampung. Mice were treated in a homogeneous environment. Before the treatment of mice, the mice were acclimatized first for 7 days so that the mice were accustomed and began to adapt.

### Research implementation

The first stage carried out is the making of basil and papaya leaf extractions. Then the second stage is the determination of the dose of glibenclamide used, which is 2.5-5 mg, then the mice used are 25 male mice with an average BW of 35gr, aged 2-3 months. The third stage is the induction of alloxan on alloxan in k(+), k(-), P1 (basil) and P2 (papaya). The fourth stage is the administration of basil and papaya leaf extracts at a dose of 14 mg/20 g BW of mice in the treatment groups, namely P1 and P2. The fifth stage is dissection and retrieval of pancreatic organs. The last stage carried out is making histology preparations using the paraffin method, and observing the histology of the pancreas of all treated mice.

## RESULT AND DISCUSSION

The phytochemical test results of fresh basil and papaya leaf extracts from 96% ethanol maceration (Table 1) contain compounds of flavonoids, alkaloids, terpenoids, tannins, and saponins. It is known that both plants contain antidiabetic compounds that can reduce blood glucose levels and as a stimulant so that insulin can be secreted by pancreatic beta cells (Ricky, 2007). The presence of these compounds is expected to have an effect on the condition of mice that experience hyperglycemia after alloxan induction.

Table 1. Phytochemical test

Phytochemical Test	Basil Leaf ( <i>Ocimum x africanum</i> Lour.)	Papaya Leaf ( <i>Carica papaya</i> L.)
Flavonoid	+	+
Alkaloid	+	+
Terpenoid	+	+
Tanin	+	+
Steroid	-	-
Saponin	+	+

The level of damage to the pancreas histology of mice shows that the treatment group induced alloxan without giving test material in figure 1(K-) has the highest damage score of  $4.0 \pm 0.0$ , the treatment group induced alloxan and given the test material basil leaf extract (P1) with a damage score of  $1.8 \pm 1$  and the group given papaya leaf leaves (P2) has a damage score of  $3.0 \pm 1.5$ . Between groups given basil leaf extract (P1) and papaya (P2) have different levels of pancreatic damage. The data of the mice pancreas histology description, the normality test was carried out, the data was normally distributed if the  $p_{count} > 0.05$ , and the results obtained  $p < 0.05$ , then the mice pancreas histology data was not normally distributed. Data analysis was continued using the nonparametric test, namely Kruskal-Wallis. Data from the Kruskal Wallis test results, obtained  $p = 0.000$  ( $p < 0.05$ ) that there is a significant difference in the improvement of pancreatic histology between groups of mice, then further post hoc Man-Withney test is carried out to determine which groups have differences in the improvement of pancreatic histology. Post Hoc Mann-Withney test data K(N) and K(-) have significant differences ( $p = 0.003$ ). The histological picture that occurs in K- shows much greater damage compared to K(N).

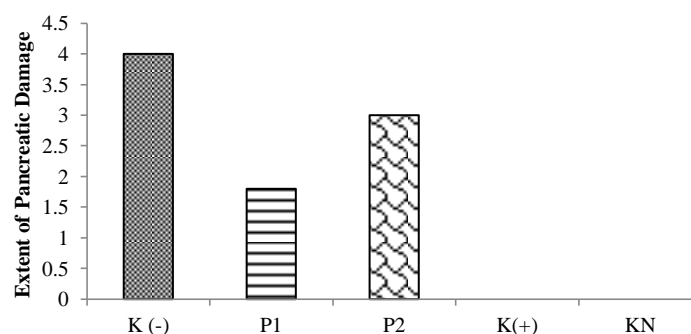


Figure 1. Mean Level of Pancreatic Damage

Alloxan induction at a dose of 160 mg/bb/day has an impact on damage to the histology of the pancreas of mice. This is in line with the research of Nurfitri et al. (2018) which says that the administration of alloxan 160 mg/bb/day can make mice experience cell damage that results in hyperglycemia. The mechanism of action of alloxan is by working selectively to damage pancreatic beta cells that produce insulin due to the accumulation of alloxan specifically through the glucose transporter, GLUT2 (Nugroho, 2006). The level of histological damage to the pancreas between KN with P1 (basil leaf extract treatment) and KN with P2 (papaya leaf extract treatment) showed significant differences in the Mann-Whitney posttest. This shows that the use of basil and papaya leaf extracts in study have the ability to repair organ damage in mice that experience hyperglycemia.

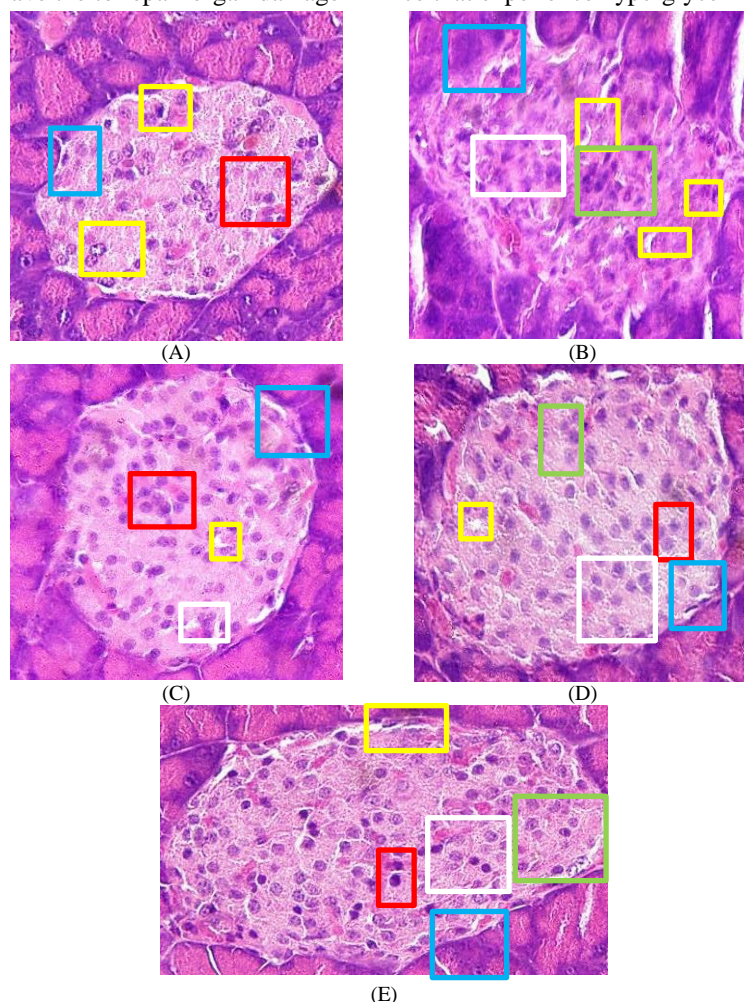


Figure 2. Pancreatic histology of hyperglycemia mice. Description: normal cells (red box), degeneration and abnormal cell shape (green box), necrosis (yellow box), much-reduced cell number (white box), Langerhans cell border (blue box)

Based on Figure 2, observation of pancreatic histology with hematoxylin eosin staining shows islets of Langerhans that are lighter in color (pink) than the pancreatic exocrine tissue which is dark in color (purple). The islets of Langerhans were circular, oval and some were duct-shaped Gupta et al. (2018). Histology of the islets of Langerhans in Figure 2 KN (only fed) showed a normal state of the cells that make up the islets of Langerhans, clear cell boundaries, degenerated and necrotic. KN control has a Langerhans islet damage level with a value of 0. Damage level 0 indicates normal Langerhans islets, no changes in Langerhans islet tissue boundaries, number of necrotic cells, and cell shape Tandi et al. (2017). The islets of Langerhans are round with clear tissue boundaries, so the islets of Langerhans can be easily distinguished from the exocrine tissue of the pancreas. Normal cells fill the endocrine tissue. The histological picture of the islets of Langerhans in the normal mice group with a score of 0 with 0% necrosis shows that the islets of Langerhans are colored lighter (pink) than the pancreatic exocrine tissue which is colored dark red (purple). According to Gupta et al. (2018) islets of Langerhans look round in general and cell boundaries are clear. Histology of the islets of Langerhans showed normal constituent cell conditions and no cell degeneration, there were alpha and beta cells, no necrotic cells, and acinus cells (exocrine pancreas) were found. Thus indicating that the islets of Langerhans are normal.

Histology of the islets of Langerhans in Figure 2 K(-) with damage level 4 shows disappearing tissue boundaries, reduced number of cells, degenerated cells and necrosis. Degeneration is seen from the morphology of cells that experience abnormal cell shape changes, while necrosis is seen from the empty space of the islets of Langerhans and black cell nuclei due to cell nucleus condensation. The results of research by Nurfitri et al. (2018) who gave alloxan as a diabetes inducing agent subcutaneously at a dose of 160 mg/kg BW was able to make mice experience hyperglycemia. The mechanism of action of alloxan is to selectively damage pancreatic beta cells that produce insulin due to the accumulation of alloxan specifically through the glucose transporter, GLUT2 (Watkins and Cooperstein, 1976). Histology of islets of langerhans in Figure 2 K(+) with a damage level of 0 showed morphological changes in clear tissue boundaries, normal cell numbers.

The administration of glibenclamide is able to repair the damage that occurs in the pancreas. Glibenclamide was used as a positive control as a comparison to see the effect of oral antidiabetics that have proven their efficacy to reduce blood glucose levels. Glibenclamide has a mechanism of action by stimulating the secretion of the hormone insulin in the granules of beta cells of pancreatic langerhans, then interaction with ATP-sensitive K channels on the beta cell membrane causes membrane depolarization then this situation causes the opening of Ca channels so that ions enter the beta cells then stimulate granules containing insulin and insulin secretion occurs (Suherman, 2007).

The dose of glibenclamide in this study is in line with previous research conducted by Nur wisdom et al. (2015) using the conversion value of Laurence and Bacharach (1964) in white rats with a conversion value of 200g to 20g mice at a dose of 0.0227 mg/35 g BW mice effectively able to repair tissue damage in the pancreas. In Figure 2 (P1) histology of the islets of Langerhans with a damage level of 1.8 in the treatment given basil extract shows the islets of Langerhans have not yet reached a normal state but there is also a significant improvement in the P1 group because the cell boundaries begin to be clear, necrosis and cell degeneration have begun to decrease. The administration of ethanol extract of basil leaves at a dose of 24.5 mg/35 g BW of mice was able to repair damage to the pancreatic islets of Langerhans, in line with previous research by Ezeani et al. (2016); Tandi et al. (2019), which was conducted on rat test animals, stated that ethanol extract of basil leaves was effective in reducing blood glucose levels. Nurbatonis et al. (2019) explained that the islets of diabetic mice that underwent repair appeared to be filled with cells so that there was a reduction in space in the islets of Langerhans, as well as clear differences between the islets of Langerhans and acinar cells.

In Figure 2 (P2), the histology of the islets of Langerhans with level 3 damage can be seen that the treatment given papaya leaf extract shows an improved picture of the islets of Langerhans but not yet to a normal state because the cell boundaries are a little clear, necrosis and cell degeneration have also not been much reduced. Papaya leaf ethanol extract given at a dose of 24.5 mg/35g BW of mice was able to repair pancreatic tissue damage. This is in line with previous research conducted by Senduk et al. (2016) found that the dose of papaya leaf extract that is effectively used in wistar rats is 500mg/kg BW.

## CONCLUSION

Based on the results of this study, it can be concluded that ethanol extract of basil leaves is more effective in repairing langerhans islet damage than papaya extract in the same dose.

## REFERENCES

- Brownlee, M.**, 2001. The pathobiology of diabetic complications diabetes. *Journal Diabetes Internal Medicine*, 54: 1615-25.
- Ezeani, C., Ifeoma, E., Theophine, O., Charles, O.**, 2016. *Ocimum x africanum* Lour. extract exhibits antidiabetic effects via inhibition of hepatic glucose mobilization and carbohydrate metabolizing enzymes. *Journal of Intercultural Ethnopharmacology*, 6(1): 22-28.
- Gupta, V., Rahul-Jain, M.L., Meena, G.S., Dangayach.**, 2018. Management of hyperglycemia in critical illness. *Journal of Medicine Internasional*, 14(3): 511
- Ikhlas.**, 2013. *Uji aktivitas antioksidan herba kemangi dengan metode DPPH*. Program Studi Farmasi Fakultas Kedokteran dan Ilmu Kesehatan. UIN Syarif Hidayatullah. Jakarta.
- Laurence, D.R. and A.L. Bacharach.**, 1964. Evaluation of drag activities pharmacometrics. *Academic Press London*, 1(1):161-162
- Nugroho, A.E.**, 2006. Hewan percobaan Diabetes melitus patologi dan mekanisme aksi diabetagonik.

*Biodiversitas*, 4(7): 378-382

- Nurbatonis, L., Kumar, V., Susatyo.,** 2019. Regenerasi sel pulau langerhans pada tikus putih (*Rattus norvegicus*) diabetes yang diberi rebusan daging mahkota dewa (*Phaleria macrocarp* (scheff.) Boerl.). efek anti diabetes rebusan buah mahkota dewa. 2 (2): 117-26
- Nurfitri, W.A., Widiastuti, E.L., Cahyani, E.N.N.,** 2018. Efek pemberian aloksan pada mencit. *Jurnal Medika Planta*, 1(4): 31
- Nurhikmah., Yuliet., Khaerati, K.,** 2015. Pengaruh pemberian ekstrak daun salam (*Syzygium polyanthum* Wight.) terhadap glibenklamid dalam menurunkan kadar glukosa darah mencit (*Mus musculus*) yang diinduksi aloksan. *Galenika Jurnal of Pharmacy*, 2(1): 24-30
- Rahman., Wati.,** 2016. Etikasi diri, kepatuhan, dan kualitas hidup pasien diabetes melitus tipe 2. *Jurnal Pustaka Kesehatan*, 5(1) : 108-113.
- Ricky.,** 2007. *Efek ekstrak daun kemangi terhadap hepatitis*. Universitas Sebelas Maret. Surakarta.
- Senduk, C.R., Palar, S., Rotty, L.W.A.,** 2016. Hubungan anemia dengan kualitas hidup pasien penyakit ginjal kronik yang sedang menjalani hemodialisis reguler. *Jurnal Keperawatan*, 11(1) : 105-110
- Tandi, J., Niswatulfahriyati., Nurmadinah., Tien, W.H.,** 2019. Uji ekstrak etanol daun kemangi terhadap kadar glukosa darah dan gambaran hispatologi pankreas tikus yang diinduksi streptozotocin. *Jurnal Mandala Pharmacon Indonesia*, 5(2): 91-90.
- Watkins, D., Cooperstein, S.J.,** 1976. Effect of alloxan on islet tissue permeability: protection and reversal by dithiols. *J Pharmacol Exp Ther.*, 199(3): 575-82.
- Wibowo, A.A.,** 2012. *Pengaruh ekstrak daun kemangi (Ocimum sanctum) terhadap Penurunan kadar kreatinin dalam darah tikus putih (Rattus norvegicus) yang diinduksi parasetamol*. Fakultas Kedokteran Universitas Sebelas Maret Surakarta.